

Live Koi Fish (Climbing Perch) Impacted in Throat: Report of 2 Cases

Professor Dr. Sudhangshu Kumar Ballav^{1*}, Dr. Seikh Farid uddin Ahmed², Dr. Noorjahan Begum³, Dr. Debnath Talukder⁴, Dr. Debbroto Ganguly⁵ and Dr. Susmita Ballav⁶

¹Ex Principal and Head of the Department of ENT & Head-Neck Surgery.

²Associate Professor, Department of Anesthesiology.

³Junior Consultant, Department of Anesthesiology.

⁴Resident Surgeon, Department of ENT & Head Neck surgery.

⁵Assistant Registrar, Department of ENT & Head Neck Surgery. Khulna Medical College and Hospital, Khulna, Bangladesh.

⁶MPH student, Tata Institute of Social Science, Mumbai, India.

***Correspondence author**

Professor Dr. Sudhangshu Kumar Ballav

Department ENT and Head-Neck Surgery

Khulna City Medical College

33 KDA Avenue

Khulna – 9100

Bangladesh

Submitted : 10 Mar 2022 ; Published : 25 Mar 2022

Citation: Ballav, S. K., Ahmed, S. F. U., Begum, N., Talukder, D., Ganguly, D., & Ballav, S. Live Koi Fish (Climbing Perch) Impacted in Throat: Report of 2 Cases. J Medical Case Repo, 2022; 4(1): 1-3.

Abstract

We present two cases of Climbing perch (*Anabas Testudineus*) locally known as Koi fish accidentally impacted in throat. The impaction of the external fins of the fish in the hypopharynx caused a bit difficulty to remove the foreign body. We are sharing our experience of successful removal of live fish from hypopharynx without any complications.

Keywords: Climbing perch, Koi fish, foreign body, hypopharynx

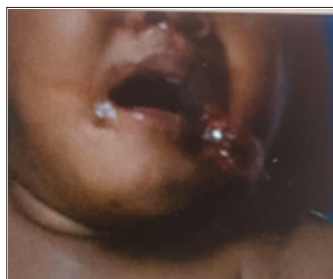Introduction

In ENT practice foreign body in aerodigestive tract is not uncommon. Accidental or deliberate ingestion of foreign body and its impaction is common in children. Sometimes impaction of foreign body may be life endangering deserving urgent removal. Various types of foreign bodies like coins, fish bone, meat bone, denture and sometimes unusual foreign body may get impacted in aerodigestive tract. Esophageal foreign bodies are more common than tracheobronchial foreign body. The impaction of fish bone in pharynx is quite common among non-vegetarians. But the impaction of live fish is a very rare instance.

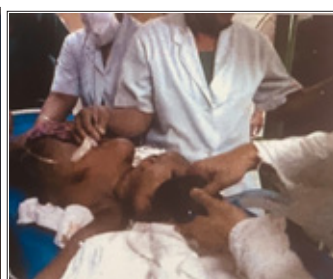Here we report 2 cases of accidental ingestion and impaction of a live climbing perch in hypopharynx. It demanded very emergency removal to save life of the victims. The climbing perch known as Koi fish in Bangladesh is a species of *Anabas testudineus*. Koi fish is freshwater fish found in rivers canals and ponds and common in Bangladesh (Tang, et al., 1974). This fish can climb and walk on grounds and survives 6-10 hours without water. The anatomy of the fish poses challenges in its removal.

Case Report 1

A 13 month's old female child was admitted into ENT ward of Khulna Medical College Hospital, Khulna, Bangladesh with history of accidental ingestion of Koi fish. The Koi fishes of different size was bought from nearby market and kept for processing. The child was playing with fishes and put one half dead fish into her mouth and swallowed. Parents with their child reached to us within hour of incident. We found that the child was drooling saliva mixed with blood. She was crying with noisy respiration. Immediately we rushed to ENT operation theater with the victim. Anesthesiologist ventilated the child by nitrous oxide halothane and oxygen through mask. We used McIntosh Laryngoscope to visualize and found the fish impacted partly into oropharynx and partly into hypopharynx with head end downwards. We removed the whole fish by the Magill forceps. We gave a second look and found no remnant of the fish but minor mucosal injury. The child was discharged on the third postoperative day with advice of liquid diet. We followed the child after 7 days and found no complications.



Case 1 : Figure 1



Case 1 : Figure 2



Case 1 : Figure 3

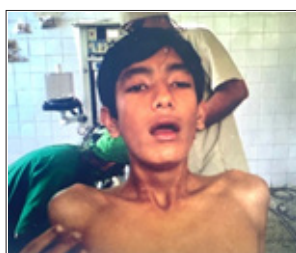

Case 1 : Figure 4

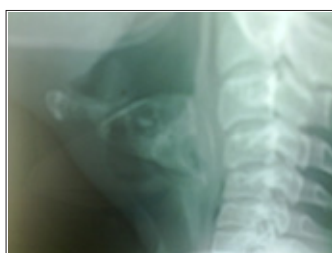Case Report 2

A 14 year's old child presented to ENT department with history of accidental ingestion of live Koi fish while catching fish in the pond. He held the fish by biting the head end and tried to catch another one. The fish got slipped into throat. Interestingly the boy gave false statement at discharge that the fish had jumped into his open mouth. It is noteworthy that Koi fish can't jump up rather it can climb and crawl on fins on land.

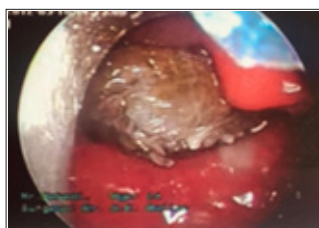The patient presented with open mouth breathing. He was unable to talk. There was no respiratory distress. In the operation theater, Anesthesiologist induced anesthesia by inhalation of nitrous oxide halothane and oxygen through mask. In this case, we also used Macintosh Laryngoscope and Magill forceps and removed the whole fish safely. On second look we found no remnant of the fish, but minor mucosal injury caused by the fins of the fish. We faced not too much difficulty. The patient was discharged on third day without any complications.



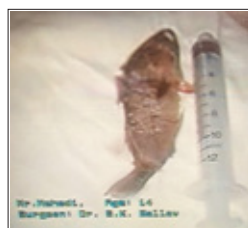
Case 2 : Figure 5



Case 2 : Figure 6



Case 2 : Figure 7



Case 2 : Figure 8

Discussion

The problems of foreign body impaction in aerodigestive tract had been in the society since time immemorial. And this problem will last forever in the human society. The patient with impacted foreign body comprised most of emergencies in ENT practice. Common foreign bodies are fish bone, meat bone, meat bolus, denture in adults and coins in children. Vegetarian people can avoid many common foreign bodies of animal origin and surely of live fish. The incidence of live fish impaction in pharynx is rare. We searched for live fish as foreign body in throat in world literature and found few case reports of live fish in aerodigestive tract (Tarasia & Mishra, 1974; Panigrahi et al., 2007).

The reported cases of live fish foreign body in pharynx stated that the head end of the fish was downward in the hypopharynx and part of the tail was in oropharynx (Tarasia & Mishra, 1974; Dunmade et al., 2006). In our cases we found similar findings.

The case-1 presented to us in such a condition that we did not go for any investigation like radiograph or even clinical examination in the ward. We relied on the history of parents and straightway took appropriate measure to remove the fish. There was minor mucosal injury in the oropharynx and hypopharynx that healed on due course. The length of the Koi fish was 7 cm and breadth 2.5 cm.

The case -2 presented to us with the history of accidental ingestion of live fish while he was catching fish in the household pond. Actual practice was to hold the fish by bite the head end to make both hands free for another catch (Pradhan et al., 2018). The struggling fish escaped and lodged into hypopharynx. Due to shame probably the boy gave false history of jumping the fish into his mouth on its own way while he tried to catch the fish. Children usually gave fabricated history out of fear of parents.

The patient was unable to talk and experienced pain with no obvious respiratory distress. He was spitting blood-stained saliva and maintained a relatively comfort posture of open mouth and extended neck. We did radiograph of neck that showed the skeleton of the fish. The length of the fish was 14 cm and breadth 4 cm. In one case report (Pradhan et al., 2018) the live fish foreign body throat was climbing perch of length 11 cm and breadth 4cm in a victim of 35 years old male in contrast to our case where the victim was 14 years male and size of the fish was 14cm by 4 cm. The site of impaction depends on the age of patient and size of the foreign body. The species of climbing perch has accessory respiratory organs for which it can survive up to 6-10 hours out of water. It has sharp fins on dorsal and ventral aspect and on both side of head with the help of which they can climb and crawl on land. These sharp fins caused injury to mucosa of pharynx. The mucosal injury may also occur during emergency removal. If the head lodged on laryngeal inlet the victim may expire within a short time.

An emergency bedside tracheostomy is recommended and required to secure airway in majority of such situation. But in our both the cases we could avoided it due to timely taken measures. Sometimes it required to remove the fish in piece meal (Tang et al., 2013).

The habit of holding one fish by biting and trying for another catch is the common cause of live fish impaction in digestive tract (Mittal et al., 2011, Dunmade et al., 2006).

Conclusion

These 2 case reports described the rare incidence of live climbing perch impaction in pharynx and its emergency management that saved the life of the victims. Emergency establishment of airway and expertise removal is necessary in cases of unusual foreign body impaction in aerodigestive tract. The habit of holding fish by biting while catching fish should be avoided.

Conflict of interest

The authors declare that there is no conflict of interest.

Funding

There is no funding source.

There is approval of Ethical committee for publication.

Written consent taken from patient's guardian.

References

1. Tarasia, H. S., & Mishra, B. N. (1974). An unusual foreign body in the trachea and left bronchus. *Indian J Otolaryngol*, 26, 110-111. <https://doi.org/10.1007/BF03048470>
2. Tang, M. L., Ching, L. S., M Med (ORL-HNS)., Brito-Mutunayagam, S., M Med (ORL-HNS)., Revadi, G., & MMed (ORL-HNS). (2013). Fish in throat: An Unusual Foreign Body. *Med J Malaysia*, 68(6), 469-70. Retrieved from <http://www.e-mjm.org/2013/v68n6/fish-in-throat.pdf>
3. Sangma, R., & ranjan, K. (2015). An Unusual Case of Foreign Body Whole Fish in Throat – A Case Report. *IOSR Journal of Dental and Medical Sciences (IOSR-JDMS)*, 14(6), 57-59. DOI: 10.9790/0853-14645759
4. Mittal, M., Yadav, R., Mody, N., & Dhond, P. V. (2011). Live Fish: Unique Foreign Body Throat. *Bombay Hospital J*, 53(4), 804-806. Retrieved from <https://www.bhj.org.in/journal/2011-5304-oct/download/804-806.pdf>
5. Dunmade, A. D., Olajide, T. G., Ologe, F. E., & Segun-Busari, S. (2006). Whole fish as an unusual foreign body in the throat: a case report. *Nigerian Journal of Otorhinolaryngology*, 3(1), 30-5. Retrieved from <https://www.ajol.info/index.php/njorl/article/view/32463>
6. Panigrahi, R., Sarangi, T. R., Behera, S. K., & Biswal, R. N. (2007). An unusual foreign body throat. *Indian journal of otolaryngology and head and neck surgery*, 59(4), 384-85. <https://doi.org/10.1007/s12070-007-0110-6>
7. Pradhan, S., Gupta, S., Dash. A. P., Mohanty, J., Rana, A. K. (2018). A rare case of live fish in Oropharynx and its management. *Int J Otorhinolaryngol Clin*, 10(2), 73-

75. Retrieved from <https://www.ajoc.com/doi/AIJOC/pdf/10.5005/jp-journals-10003-1296>

Copyright: ©2022 Sudhangshu Kumar Ballav. This is an open-access article distributed under the terms of the Creative Commons Attribution License, which permits unrestricted use, distribution, and reproduction in any medium, provided the original author and source are credited.