

## Two Natural Births with Unremoved Iuds Causing Bladder Stone Formation Due to IUD Migration: A Rare Case

Tan Duy Vu\*, Hieu Trung Nguyen, Anh Lan Tran, Son Diem

<sup>1</sup>Department of Surgery, Yen Bai Provincial General Hospital, Yen Bai, Phnom Penh, Cambodia.

<sup>2</sup>Board of Directors, Yen Bai Provincial General Hospital, Yen Bai, Phnom Penh, Cambodia.

### \*Corresponding author

**Tan Duy Vu,**  
Department of Surgery,  
Yen Bai Provincial General Hospital,  
Village 1, Gioi Phien Commune,  
Yen Bai City, Yen Bai Province,  
Phnom Penh, Cambodia

Submitted : 1 Jan 2024 ; Published : 8 Feb 2024

**Citation:** Vu Tan, D., Nguyen, H. T., Tran, A. L., & Diem, S. (2024). Two Natural Births with Unremoved Iuds Causing Bladder Stone Formation Due to IUD Migration: A Rare Case. J Medical Case Repo, 6(1):1-5. DOI : <https://doi.org/10.47485/2767-5416.1056>

### Abstract

*Background: Intrauterine Device (IUD) Multiload 375 is a method of contraception widely used worldwide. One of the rare complications is that the IUD punctures the uterus and moves into the bladder. Common manifestations are recurrent urinary tract infections and bladder stones. A long-term and neglected IUD increases the risk of uterine perforation and migration to other organs.*

*Diagnosis: Clinical history, Cystoscopy, Transvaginal Ultrasound (US) or Computed Tomography helps confirm the diagnosis.*

*Case Report: We report successful surgical treatment of a 39-year-old woman who neglected to insert a Multiload 375 IUD for 16 years, but still experienced 2 subsequent vaginal deliveries and eventually developed UTI. Bladder stone formation caused by the passage of the Multiload 375 intrauterine device through the bladder.*

*Conclusions: Urologists should consider bladder foreign bodies as a displaced IUD in women with recurrent lower urinary tract infections or bladder stones, with a history of IUD use. The moving IUD needs to be removed through cystoscopy, laparoscopy, or open surgery. Proper monitoring and education for women's health before and after IUD insertion helps to detect complications in a timely manner.*

**Keywords:** Bladder stones; Intrauterine device displacement; Contraception; Recurrent urinary tract infections; Natural birth.

### Introduction

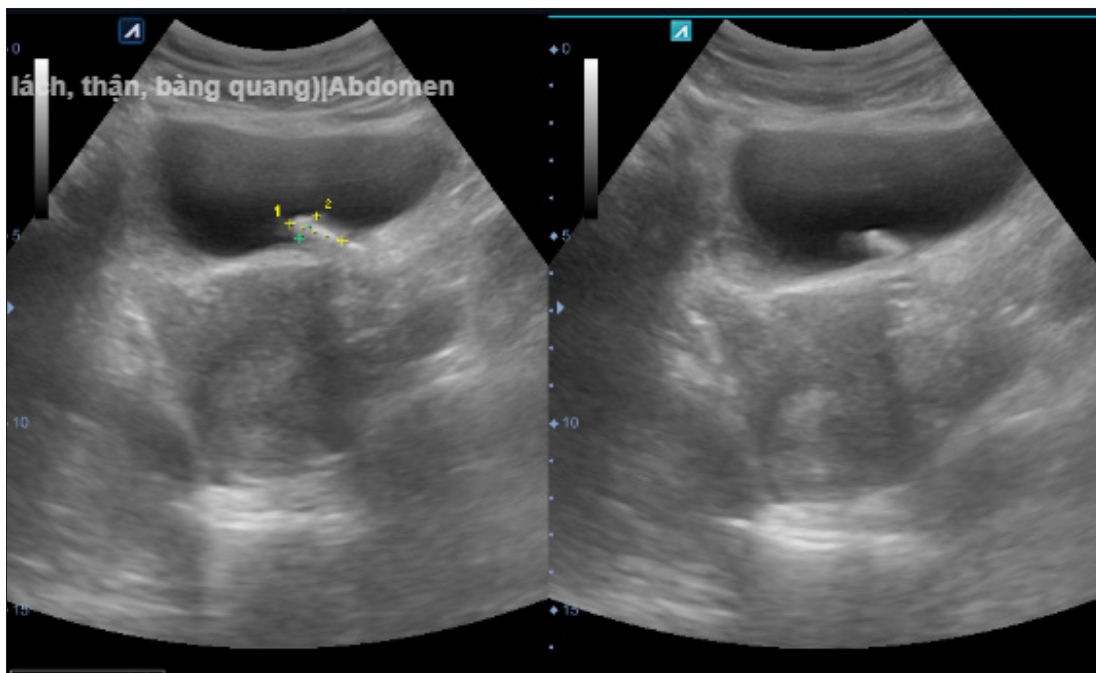
The Multiload 375 Intra Uterine Device (IUD) is a widely used method of contraception worldwide. IUDs have many advantages such as cost savings, high efficiency low complication rate [1]. However, some complications of the IUD have been reported. One of these complications is that the IUD perforates the uterus and travels to nearby organs such as the peritoneum, intestines, blood vessels, and bladder [2-4]. The IUD moving outside the uterus is an uncommon but dangerous complication. The reported complication rate of uterine perforation is approximately 1/1000 of IUD insertions [5]. Uterine perforation with transvesical migration is an uncommon complication, most commonly presenting with recurrent Urinary Tract Infections (UTI) and bladder stones [6,7]. IUDs that move into the bladder should be removed through cystoscopy, laparoscopy, or open surgery [8,9]. Here we report the successful surgical treatment of a 39-year-old woman who neglected to insert a multiload 375 IUD for 16 years, but still underwent 2 subsequent vaginal deliveries and

eventually developed a UTI. Bladder stones caused by the Multiload 375 intrauterine device moving into the bladder.

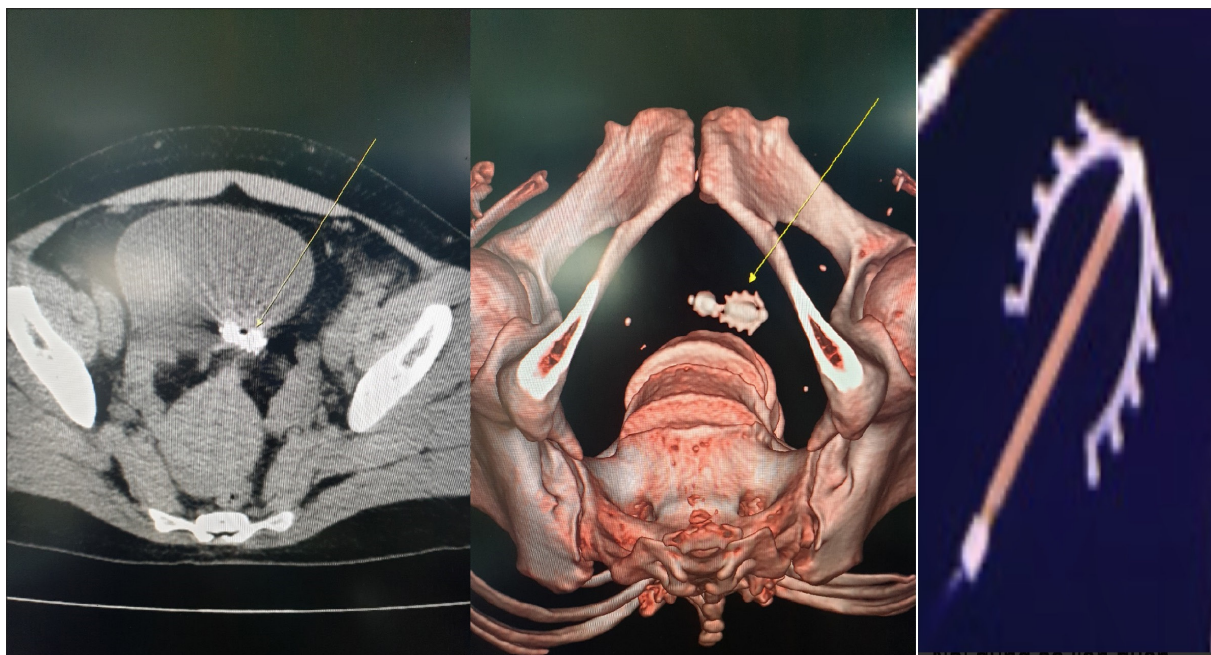
### Presenting The Case

A 39-year-old woman, living in a rural area, came to our center with painful, urgent urination for 4 months. She went to multiple health care centers and was diagnosed with a Urinary Tract Infection (UTI) and she took multiple antibiotic regimens. About 1 month prior to admission, a new onset of dysuria increased markedly periodically during menstruation. She gave birth to three children naturally and had regular periods. She has no history of surgery in the past. In 2007, 1 year after giving birth to her first child, she had the Multiload 375 IUD inserted and it appeared to be forgotten and unnoticed in subsequent births in 2009 and 2019. General and regional examination her pots are unremarkable. Laboratory test results were normal and there were no bacteria on the urine culture. Abdominal ultrasonography performed showed an unusually

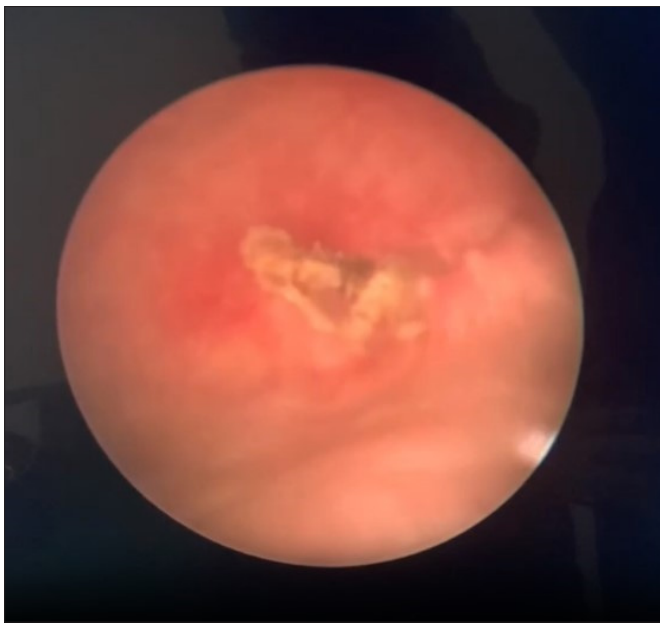
shaped gallstone in the ceiling of the bladder (Figure 1). The urologist suspected a possible bladder remnant and ordered cystoscopy and computed tomography of the urinary tract with rendering (Figure 2). Rigid cystoscopy was performed 3 days later and revealed a white multiload 375 IUD-like relic attached to the posterior wall of the bladder with calculi adhering to its surface (Figure 3) (Video 1).



**Figure 1:** Image of an obstruction in the bladder (yellow highlighted area).



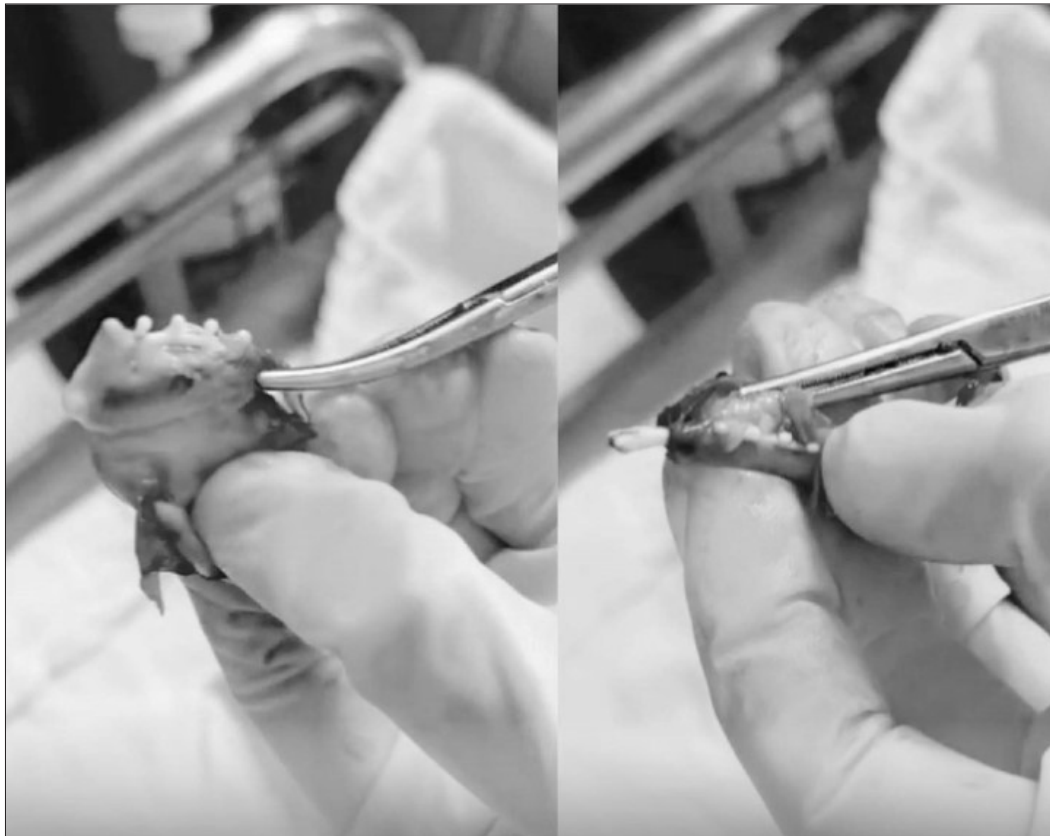**Figure 2:** Computed tomography image of the IUD-like object Multiload 375 (Yellow arrow).



**Figure 3:** Cystoscopy image of the Multiload 375 instrument in the bladder.

The trial of endoscopic IUD removal was unsuccessful because it adhered to the bladder wall. The patient was asked to provide a detailed history of contraceptive use and she reported having an IUD inserted 16 years ago at a local medical center. She did not return to the medical center for a follow-up visit because she was not asked to do so. She had been sexually active for the past 16 years, became pregnant twice, and gave birth naturally at her local health center, approximately 2 years and 12 years after the IUD insertion, respectively. In both pregnancies, she did not report to the medical center. After consultation with the patient, open surgical removal of the transvesical IUD under endotracheal anaesthesia was decided.

Results in extra peritoneal open surgery showed that the Multiload 375 intrauterine device penetrated the posterior wall of the bladder, on the surface of the stone. It was dissected from the surrounding mucosa and successfully removed (Figure 4). The bladder wall was repaired and a Foley catheter was in place. The patient was discharged after 5 days without complications, and the catheter was removed on the tenth postoperative day.



**Figure 4:** The Multiload 375 IUD is removed.



## Discussion

The IUD is considered a relatively safe, effective, simple, economical and reversible method of contraception. Approximately 40% of women of childbearing age choose an IUD as a method of contraception [1]. Common adverse reactions and complications associated with IUD insertion include bleeding, uterine perforation and ectopic pregnancy, infection, dysmenorrheal abnormal menstrual volume septic abortion and endometrial tumor. However, in recent years, the number of cases of IUDs being missed, placed abnormally is increasing, causing many complications for patients. Many reports indicate that factors such as lactation period, uterine congenital abnormalities, previous pelvic surgery, postpartum period, and IUD insertion by inexperienced physicians can increase risk [5]. The most common types of IUD currently in use are the copper-releasing IUD (TCu-380A) and the Levonorgestrel-Releasing IUD (LNG- IUD). Levonorgestrel-releasing formulations are expensive and are rarely used in rural areas, and IUDs are usually removed after up to 5 years. According to a study by [10] reported that the rate of uterine perforation due to the M<sub>2</sub>Cu II IUD was higher than that of other IUDs such as T-type, copper-type, O-type, and uterine cavity type. In our patient, the use of the Multiload 375 copper release Device was rare however she was kept too long for 16 years and had 2 natural births in 2009 and 2019. Uterine perforation is the most dangerous and feared complication, the IUD causing perforation of the uterus into the bladder and stone formation is rare and accounts for 1% to 3% of reports [2-4]. It is primarily treatment-induced primary occurs at the time of IUD insertion and presents immediately as pain and vaginal bleeding. Occasionally, spontaneous (secondary) perforation may occur later, after IUD insertion, possibly due to a chronic inflammatory process or spontaneous uterine contractions [6,7]. We believe that our patient had a secondary perforation of the uterus and subsequent insertion of the IUD into the posterior wall of the bladder, as she did not have any immediate symptoms after IUD insertion and had undergone 2 After natural birth, we believe that the development of the fetus through the patient's 2 normal births is also one of the factors that cause the IUD to move outside the uterus.

In order to diagnose a moving IUD, important signs are the absence of the device string at the cervical opening and or the presence of an intrauterine pregnancy. Tran's vaginal ultrasound is the best method to locate suspected metastases. Studies have shown that up to 50% of a displaced IUD can be missed by conventional abdominal ultrasound [5,10]. Abdominal and pelvic radiographs may also be helpful because the device is contrast-enhanced. In our patient, the radiologist detected an abnormal abdominal ultrasound image in the bladder region and alerted the urologist. Cystoscopy is recommended if the patient's symptoms suggest bladder involvement [8]. During laparoscopy (Figure 3) we detected a partial intraluminal IUD with surrounding calculi which was difficult to assess as a whole. We gave the patient a computed tomography scan of the urinary tract with rendering (Figure 2) which we diagnosed as the Multiload 375 instrument as soon as the images were available and that helped us plan the surgery

The World Health Organization recommends removing the moved IUD as soon as possible [11]. Surgical removal should be considered even in asymptomatic patients once it has migrated out of the uterus. The recommendation is to use minimally invasive methods where possible, including hysteroscopy, cystoscopy, colonoscopy, or laparoscopy, depending on where the IUD is placed. If the device is embedded in an organ such as the bladder or bowel, the device should not be removed by minimally invasive methods; exploratory laparoscopic surgery should be performed [9]. In the same way, as in the case discussed, if the IUD is close to a blood vessel or it is not completely visible, more invasive methods are recommended by an experienced surgeon [8,10]. Our patient had a partial IUD located in the bladder wall and firmly attached to the muscle layer, which we found difficult to apply laparoscopic surgery. After discussing and agreeing with the patient, we applied open surgery the surgery was successful after 90 minutes and obtained the Multiload 375 type IUD located deep in the bladder muscle layer (Figure 4). Uterine perforation due to an IUD needs to be detected early because failure to do so will lead to instrument displacement and potentially dangerous complications. Women should be counseled about possible complications and the need for regular follow-up, removal of the IUD after no more than 5 years [5,11]. Our patient had an IUD for 16 years and she seemed to have forgotten about it, even though she later had 2 successful natural births at her local medical center. We consider the lack of device awareness when not returning to the health center for follow-up visits and the lack of discretion in local pregnancy management as identified factors in our patients. This IUD moves into the bladder with no specific symptoms, but its symptoms are similar to those of a UTI, a bladder stone [5,6]. Many patients including our case go to multiple doctors seeking treatment without realizing that the main problem is an incomplete diagnosis. We suggest that women with recurrent UTIs should be screened for any persistent risk factors, such as stones or foreign bodies [1]. A detailed history of contraception should not be overlooked, as that was the most important diagnostic tip in our patient.

## Conclusion

Urologists should think of bladder foreign bodies as a displaced IUD in women with recurrent lower urinary tract infections or bladder stones, with a history of IUD use. The diagnosis of a moving IUD should be made easy with the clinical history, ultrasound, and pelvic radiographs. The moving IUD needs to be removed through cystoscopy, laparoscopy, or open surgery. Proper monitoring and education for women's health before and after IUD insertion helps to detect complications in a timely manner.

## List of Abbreviations

IUD = Intrauterine contraceptive device,  
US = Ultrasonography,  
UTI = urinary tract infection.

Patients Consented to Participation and Publication.

## Publishing Consent

Written and signed consent was obtained from the patient and the authors to publish this case report and accompanying images.

## Benefit

The authors report no conflicts of interest in this work.

## Financial Support

There was no funding.

## References

1. Hsia JK, Creinin MD. Intrauterine Contraception. *Semin Reprod Med.* 2016 May;34(3):175-82. DOI: 10.1055/s-0036-1571438. Epub 2016 Mar 4. PMID: 26947701.
2. Dimitropoulos K, Skriapas K, Karvounis G, Tzortzis V. Intrauterine device migration to the urinary bladder causing sexual dysfunction: a case report. *Hippokratia.* 2016 Jan-Mar;20(1):70-72. PMID: 27895447; PMCID: PMC5074402.
3. Boushehry R, Al-Taweel T, Bandar A, Hasan M, Atnuos M, Alkhamis A. Rare case of rectal perforation by an intrauterine device: Case report and review of the literature. *Int J Surg Case Rep.* 2022 Oct;99:107610. DOI: 10.1016/j.ijscr.2022.107610. Epub 2022 Sep 8. PMID: 36116303; PMCID: PMC9568710.
4. Briceno SA, Brown MR, Herson AB, Fischer ST, Healey KD, Miller BT, W Fountain M. Long-Term Retained Lippes Loop Intrauterine Device Causes Vesicouterine Fistula. *Cureus.* 2023 Apr 27;15(4):e38217. DOI: 10.7759/cureus.38217. PMID: 37252518; PMCID: PMC10224777.
5. Rowlands S, Oloto E, Horwell DH. Intrauterine devices and risk of uterine perforation: current perspectives. *Open Access J Contracept.* 2016 Mar 16;7:19-32. DOI: 10.2147/OAJC.S85546. PMID: 29386934; PMCID: PMC5683155.
6. Liu G, Li F, Ao M, Huang G. Intrauterine devices migrated into the bladder: two case reports and literature review. *BMC Womens Health.* 2021 Aug 16;21(1):301. DOI: 10.1186/s12905-021-01443-w. PMID: 34399735; PMCID: PMC8365895.
7. De Silva WSL, Kodithuwakku KASUA, Aponsu GUE, Rathnayake RMM, Rajasegaram E. A large bladder stone caused by the intravesical migration of an intrauterine contraceptive device: a case report. *J Med Case Rep.* 2017 Oct 22;11(1):293. DOI: 10.1186/s13256-017-1461-6. PMID: 29058619; PMCID: PMC5651565.
8. Vahdat M, Gorginzadeh M, Mousavi AS, Afshari E, Ghaed MA. Cystoscopic removal of a migrated intrauterine device to the bladder; a case report. *Contracept Reprod Med.* 2019 Jul 1;4:7. DOI: 10.1186/s40834-019-0089-x. PMID: 31304041; PMCID: PMC6600896.
9. Han X, Yang H. Successful endoscopic management of 3 cases of translocated intrauterine devices: a case report. *Ann Palliat Med.* 2021 Feb;10(2):2371-2378. DOI: 10.21037/apm-21-184. Epub 2021 Feb 18. PMID: 33615801.
10. Goldbach AR, Hava S, Patel H, Khan M. IUD embedment in the fallopian tube: An unexpected location for a translocated IUD. *Radiol Case Rep.* 2018 Jun 7;13(4):788-792. DOI: 10.1016/j.radcr.2018.04.030. PMID: 30002782; PMCID: PMC6041366.
11. Mechanism of action, safety and efficacy of intrauterine devices. Report of a WHO Scientific Group. *World Health Organ Tech Rep Ser.* 1987;753:1-91. PMID: 3118580.

**Copyright:** ©2024 Tan Duy Vu. This is an open-access article distributed under the terms of the Creative Commons Attribution License, which permits unrestricted use, distribution, and reproduction in any medium, provided the original author and source are credited.