

Case Report On Rare Co-Occurrence of Complicated Acute Appendicitis and Ovarian Cyst Rupture

Nurhussen Mossa Ahmed^{1*}, Alemu Dima Jirru², Terefayehu Belay Hailu³, Sitotaw Mossa Ahmed⁴

¹Department of Surgery, Yekatit 12 Hospital Medical College, Addis Ababa, Ethiopia

²Department of Surgery, Terunesh Beijing General Hospital, Addis Ababa, Ethiopia

³Department of Obstetrics and Gynecology, Terunesh Beijing General Hospital, Addis Ababa, Ethiopia

⁴Department of Statistics, Jinka University, Jinka, Ethiopia

*Corresponding author

Nurhussen Mossa Ahmed,
Department of Surgery,
Yekatit 12 Hospital Medical College,
Addis Ababa,
Ethiopia.

Submitted : 23 Mar 2024 ; Published : 10 May 2024

Citation: Ahemd, N. M., Jirru, A. D., Hailu, T. B., Ahmed, S. M. (2024). Case Report On Rare Co-Occurrence of Complicated Acute Appendicitis and Ovarian Cyst Rupture *J Medical Case Repo*, 6(2):1-4. DOI : <https://doi.org/10.47485/2767-5416.1077>

Abstract

Acute appendicitis is the most common surgical emergency, and is also the most common cause of non-gynecological pelvic pain. Female patients presenting with abdominal pain in the presence of an underlying gynecological pathology such as ectopic pregnancy, threatened abortion, ovarian cyst, tubo-ovarian abscess or pelvic inflammatory disease can mimic acute appendicitis, potentially complicate the clinical picture and affect the diagnostic accuracy. Open or laparoscopic surgery is the mainstay of management for Complicated Appendicitis. Our patient was operated having signs and symptoms of pelvic peritonitis, with intraoperative finding of pelvic cavity blood with right ruptured ovarian simple cyst. She also had significant appendiceal abscess contained by omentum, terminal ilium, cecum and sigmoid colon with eaten up appendix in the abscess. This is a rare co-occurrence of appendiceal abscess with ruptured ovarian cyst, only one previous published case report of acute appendicitis with ruptured ovarian cyst.

Keywords: complicated appendicitis, ovarian cyst rupture.

Introduction

Acute appendicitis is one of the most common general surgical emergencies worldwide, most often occurs between the ages of 10 and 20 years. Classically, it is diagnosed with periumbilical coliclike

Pain. By virtue of peritoneal irritation, the pain begins to be localized and sharpens within 24 hours to the right lower quadrant associated with nausea, vomiting and loss of appetite. With Imaging abdominal and pelvic computed tomography screening or ultrasonography finding of appendix diameter greater than 6 millimeter thickened wall, lymphadenopathy, surrounding fluid accumulation and fat stranding [1-3].

The differential diagnosis includes Crohn disease, ruptured ovarian cyst, ovarian torsion, round ligament syndrome, salpingitis, mittelschmerz, ectopic pregnancy, tubo-ovarian abscess, endometriosis, pelvic inflammatory disease, gastroenteritis, right-sided colitis, renal colic, kidney stones, testicular torsion, and other nondescript gastroenterological issues [4].

Female patients presenting with abdominal pain in the presence of an underlying gynaecological pathology can potentially

complicate the clinical picture and affect the diagnostic accuracy [5].

Case Summary

A 26-year-old female presented to Tirunesh Beijing General Hospital emergency department with a complaint of abdominal pain of 7 days duration. The pain starts periumbilical and latter shifted to the whole lower abdomen. It is associated with vomiting of two episodes, fever, Anorexia and nausea. She had no failure to pass feces, flatus or abdominal distension. There was no urinary frequency, urgency, dysuria, vaginal bleeding or vaginal discharge. She is para one women, gave uneventful spontaneous vaginal delivery two years back. Her menstruation is regular and last normal menstrual period was a week back. She was treated with oral antibiotics at local health center for five days then referred to this Hospital when the disease condition showed no improvement.

On physical examination, she was acutely sick looking with pulse rate of 112 and Blood pressure of 115/65 mmHg and Axillary temperature of 37.8 degree centigrade. She had full abdomen with direct and rebound tenderness over whole lower

abdomen with guarding and rigidity. There was some soft stool in the rectum and on per vaginal examination there was no cervical motion tenderness or blood on examining fingers. On investigation white blood cells of 13,000 with Neutrophil count of 84% and platelet count of 332,000. Her urine B-HCG was negative. Abdominopelvic ultrasound report was 4.3x3.8 cm well defined anechoic thin walled right adnexal cystic lesion. Appendix was dilated measuring 10mm and noncompressible with minimal periappendiceal collection. The patient then was resuscitated until adequate urine output. Ceftriaxone 1 gram IV bid and metronidazole 500mg IV TID started. With her informed written consent, she was taken to the operating theater with preoperative impression of pelvic peritonitis secondary to perforated appendicitis rule out ovarian cyst rupture. The abdomen was cleaned with povidone-iodine and draped, then the peritoneal cavity was entered through an infraumbilical midline incision. The intraoperative finding was 50cc blood in the pelvic cavity with ruptured right ovarian cyst but no active bleeding (Figure 1). There was also 5cmx6cm inflammatory mass in the right lower quadrant extending to the midline of lower abdomen formed by cecum, terminal ileum, sigmoid colon, omentum and small bowel mesentery. Upon Gentle blunt dissection there was 75cc thick offensive puss contained in the inflammatory mass and appendix was eaten up in the abscess (Figure 2).

The pelvic cavity blood sucked out, the abscess drained and purse string suture applied on the cecum circumferentially burying eaten up appendicular base. The rupture simple right ovarian cyst cystectomy done. Abdomen lavaged with Warm Normal saline. Drain left at right lower quadrant abscess cavity. The abdomen was closed in layers. The patient was extubated on the table and transferred to the postanesthesia care unit with stable vital signs.

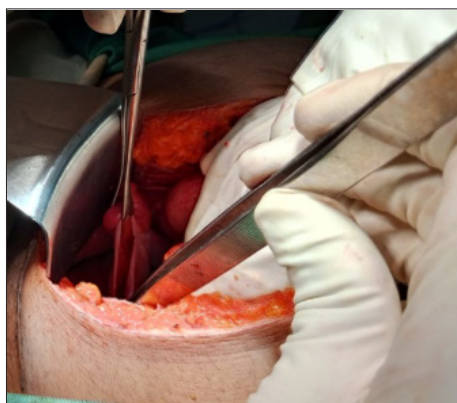

Figure 1: Shows intraoperative finding of right ruptured ovarian cyst

On first postoperative (pod) day the drain output was 20 ml serosanguineous and patient with normal vital sign. She started sips. On the second pod the drain removed since the output was 10ml serosanguinous over 24hr. Patient was taking IV antibiotics in the hospital then discharged on the 7th pod with improvement. She was having postoperative follow up at surgical referral clinic for 3 months. She had improved in her general condition and was already started to routine house hold

and job activity.

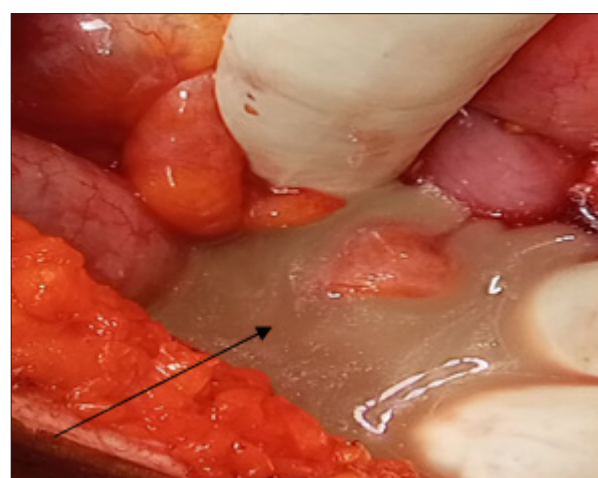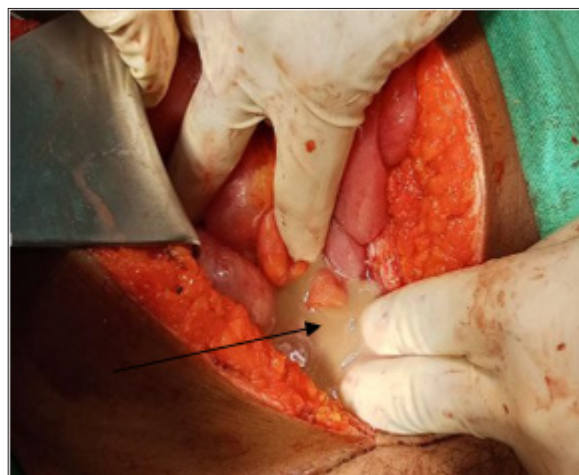


Figure 2: Shows intraoperative findings of abscess from ruptured appendicitis

Discussion

General surgeons are often asked to evaluate acute abdominal pain. The differential diagnosis of abdominal pain is broad, and includes disorders of the urogenital, gynecologic, vascular and gastrointestinal system. Abdominal pain may be caused by infectious, inflammatory, anatomic, or neoplastic processes. Acute appendicitis is the most common surgical emergency, and is also the most common cause of non-gynecological pelvic pain. Many gynecologic conditions such as ectopic pregnancy, threatened abortion, ovarian cyst or tubo-ovarian abscess or pelvic inflammatory disease can mimic acute appendicitis, making the diagnosis unclear [6-8].

Complicated appendicitis is defined as the presence of gangrene, appendiceal perforation, serious periappendiceal inflammation, peritonitis, mass formation, intraabdominal or pelvic abscess [9-11]. Some of the factors associated with the presentation of complicated appendicitis are extremes of age, appendicoliths and late presentation [12-14]. In our case her late presentation (7 days) from symptom onset to our hospital is one risk factor for the complicated appendicitis, but the concomitant presence of ruptured ovarian cyst forces us to consider multiple differential diagnosis.

Cases of complicated appendicitis, which include perforated appendicitis and gangrenous appendicitis, may progress to acute peritonitis, a condition that necessitates emergency surgery regardless of the time of development. Current evidence shows that surgical treatment of patients presenting with appendiceal phlegmon or abscess is preferable to accompanied with antibiotic oriented treatment in the reduction of the length of hospital stay and need for readmissions. Nowadays, laparoscopic appendectomy has surpassed open appendectomy in treatment of appendicitis. [15, 16]. Our patient was septic with leukocytosis, tachycardia and with signs of pelvic peritonitis having appendiceal abscess which needs emergency surgery. Open surgery was done due to lack of laparoscopic service in the setup. Most ruptured ovarian cysts (80.8%) can be managed conservatively, and 19.2% of the patients require a surgical intervention [17]. However, our case was complicated with concomitant complicated appendicitis which mandates surgical intervention

Conclusion: The simultaneous occurrence of appendiceal abscess with ruptured ovarian cyst is rare, we found only one previous case report of acute appendicitis with ruptured ovarian cyst [18]. The pathophysiological mechanism(s) behind this co-occurrence needs further studies. The co-occurrence makes diagnosis and decision making for operation challenging and delayed especially in resource limited setting, where imaging diagnostics of choice like CT scan are unavailable. In such a dilemma appropriate patient history, physical exam and clinical decision are paramount and lifesaving.

Acknowledgments

The authors acknowledge everybody who participated in the management of the patient to achieve the best outcome for her. We also extend our deepest gratitude to the Terunesh Beijing General Hospital administration for their permission to use the patient's medical record.

Consent

Institutional approval was not required for the publication of these case details. A well informed verbal consent was obtained from the patient for publication of this case report and any accompanying intraoperative images.

Disclosure

The authors report no conflicts of interest in this work.

Abbreviations

B-HCG : Human chorionic gonadotropin

IV : Intravenous

POD : Post operative day

TID : Three times a day

References

1. Stewart B, Khanduri P, McCord C, et al. Global disease burden of conditions requiring emergency surgery. *Br J Surg.* 2014;101(1):(e9–22.). DOI: <https://doi.org/10.1002/bjs.9329>
2. Humes DJ, Simpson J. Acute appendicitis. *BMJ.* 2006;333(7567):530–534. DOI: <https://doi.org/10.1136/bmj.38940.664363.ac>
3. Krzyzak M, Mulrooney SM. Acute Appendicitis Review: Background, Epidemiology, Diagnosis, and Treatment. *Cureus.* 2020;12(6):e8562. DOI: <https://doi.org/10.7759/cureus.8562>
4. Jiang J WY, Tang Y, Shen Z, Chen G, Huang Y, Zheng S, Zheng Y, Dong R. A novel nomogram for the differential diagnosis between advanced and early appendicitis in pediatric patients. *Biomark Med.* 2019;13(14):1157–1173. DOI: <https://doi.org/10.2217/bmm-2019-0036>
5. Amer E. Mimickers of appendicitis. Doubts, Problems and Certainties about Acute Appendicitis 2022.
6. Boyd CA, Riall TS. Unexpected Gynecological Findings during Abdominal Surgery. *Curr Probl Surg.* 2012 April;49(4):195–251. DOI: <https://doi.org/10.1067%2Fj.cpsurg.2011.12.002>
7. Karam AR, Birjawi GA, Sidani CA, Haddad MC. Alternative diagnoses of acute appendicitis on helical CT with intravenous and rectal contrast. *Clin Imaging.* Mar-Apr; 2007;31(2):77–86. DOI: <https://doi.org/10.1016/j.clinimag.2006.12.023>
8. Vandermeer FQ, Wong-You-Cheong JJ. Imaging of acute pelvic pain. *Clin Obstet Gynecol.* Mar;2009 52(1):2–20. DOI: <https://doi.org/10.1097/grf.0b013e3181958173>
9. Horn AE, Ufberg JW. Appendicitis, diverticulitis, and colitis. *Emerg Med Clin N Am.* 2011;29(2):347–368. DOI: <https://doi.org/10.1016/j.emc.2011.01.002>
10. Körner H, Söndena K, Söreide JA, et al. Incidence of acute nonperforated and perforated appendicitis: agespecific and sex-specific analysis. *World J Surg.* 1997;21(3):313. DOI: <https://doi.org/10.1007/s002689900235>
11. Mariage M, Sabbagh C, Grelpois G, Prevot F, Darmon I, Regimbeau JM. Surgeon's Definition of Complicated Appendicitis: A Prospective Video Survey Study. *Euroasian J Hepatogastroenterol.* 2019 Jan-Jun;9(1):1–4. DOI: <https://doi.org/10.5005/jp-journals-10018-1286>
12. Broker MEE, van Lieshout EMM, van der Elst M, Stassen LP, Schepers T. Discriminating between simple and perforated appendicitis. *J Surg Res.* 2012;176(1):79–83. DOI: <https://doi.org/10.1016/j.jss.2011.09.049>
13. Livingston EH, Woodward WA, Sarosi GA, Haley RW. Disconnect between incidence of nonperforated and perforated appendicitis: implications for pathophysiology and management. *Ann Surg.* 2007;245(6):886–92. DOI: <https://doi.org/10.1097/01.sla.0000256391.05233.aa>

-
14. Ishiyama M, Yanase F, Taketa T, Makidono A, Suzuki K, Omata F, Saida Y. Significance of size and location of appendicoliths as exacerbating factor of acute appendicitis. *Emerg Radiol.* 2013;20(2):125-130.
DOI: <https://doi.org/10.1007/s10140-012-1093-5>
 15. Varadhan KK, Neal KR, Lobo DN. Safety and efficacy of antibiotics compared with appendicectomy for treatment of uncomplicated acute appendicitis: meta-analysis of randomised controlled trials. *BMJ.* 2012;344:2156.
DOI: <https://doi.org/10.1136/bmj.e2156>
 16. Cheng Y XX, Lu J, et al. Early versus delayed appendicectomy for appendiceal phlegmon or abscess. *Cochrane Database Syst Rev.* 2017;6:CD011670. DOI: <https://doi.org/10.1002%2F14651858.CD011670.pub2>
 17. Kim JH, Lee SM, Lee J-H, Jo YR, Moon MH, Shin J, et al. Successful Conservative Management of Ruptured Ovarian Cysts with Hemoperitoneum in Healthy Women. *PLoS ONE.* March 7, 2014;9(3):e91171.
DOI: <https://doi.org/10.1371/journal.pone.0091171>
 18. Oktay MM, Altinsoy KE, GÖL M, Kaya ÖM, Özdemir S. A case report: Co-existence of Acute Appendicitis and Ovarian Cyst Rupture. *Zeugma Biological Science.* 2023;4(2):1-5.
DOI: <https://doi.org/10.55549/zbs.1258042>

Copyright: ©2024 Nurhussen Mossa Ahmed. This is an open-access article distributed under the terms of the Creative Commons Attribution License, which permits unrestricted use, distribution, and reproduction in any medium, provided the original author and source are credited.