

## Translation of Electrocardiography and Genetics in Arrhythmogenic Left Ventricular Cardiomyopathy

Stefan Peters

UEK Norden, Internal Medicine and Cardiology, Germany.

**\*Corresponding Author****Prof.Dr.med.Stefan Peters,**UEK Norden, Internal Medicine and Cardiology,  
Osterstr. 110, 25606 Norden.

Submitted : 8 May 2024 ; Published : 3 June 2024

**Citation:** Peters, S. (2024). Translation of Electrocardiography and Genetics in Arrhythmogenic Left Ventricular Cardiomyopathy. I J cardio & card diso; 5(2):1-5. DOI : <https://doi.org/10.47485/2998-4513.1033>

**Abstract**

*Translational cardiology combines different techniques in order to get a correct diagnosis (precision medicine). In a rare disease called arrhythmogenic left ventricular cardiomyopathy caused by non-desmosomal gene mutations 12-lead ECG and results of genetics were combined and analyzed. In a few gene mutations ECG findings were highly specific and predicts gene mutation, like desmoplakin, phospholamban, desmoglein-2, desmocollin-2, TMEM43, lamin A/C, and probably filamin C mutation.*

*With the help of simple 12-lead ECG technique a precise prediction of specific gene mutation can be made.*

**Keywords:** Arrhythmogenic left ventricular cardiomyopathy; T-wave inversions; low voltage in limb leads; developing right bundle branch block; anteroseptal R-wave reduction.

**Introduction**

Since 2020 arrhythmogenic cardiomyopathy includes a right dominant form, a biventricular form and a left dominant form. Already in 2004 Carvajal syndrome was first described in Ecuador within families (Kaplan et al., 2004). This syndrome includes a slightly dilated, poor contracting left ventricle and hair and skin abnormalities with curly hair and plantopalmar keratosis. The genetic background were mutations of the desmoplakin gene.

Primarily it was thought to be a special form of dilated cardiomyopathy. But in ongoing years, with the help of cardiac MRI findings with severe fibrosis, the similarities with Naxos disease with similar aspects of hair and skin were more and more evident.

In 2020 Domenico Corrado characterized the term of arrhythmogenic left ventricular cardiomyopathy with extensive fibrosis of the left ventricle and ring-like appearance in late enhancement in cardiac MRI (Corrado et al., 2020). Low voltage in limb leads is due to the fact that the left ventricle is poor contracting, T-wave inversions in inferolateral leads are often seen in biventricular or left dominant forms characterizing reduced left ventricular function.

The most important mutations are: desmoplakin ( in about 12 % of cases), phospholamban (in Dutch population about 15%), lamin A/C, filamin C, desmoglein-2, desmocollin-2, desmin, and TMEM43.

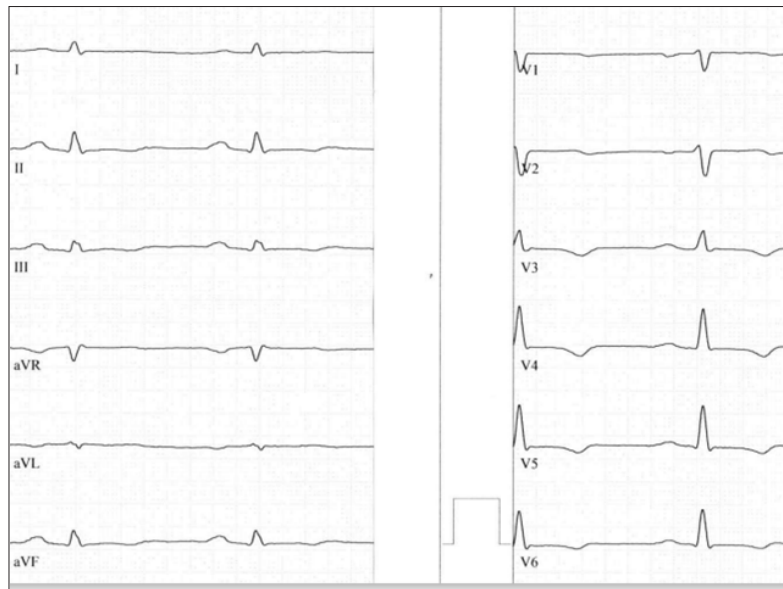
**ECG and genetics****Desmoplakin**

Desmoplakin is the most important gene mutation in arrhythmogenic left ventricular cardiomyopathy with 'hot phases' characterised by chest pain, troponin release mimicking myocarditis. The ECG present low voltage in limb leads, and T-wave inversions or flattening inferolateral only in leads V5 und V6.

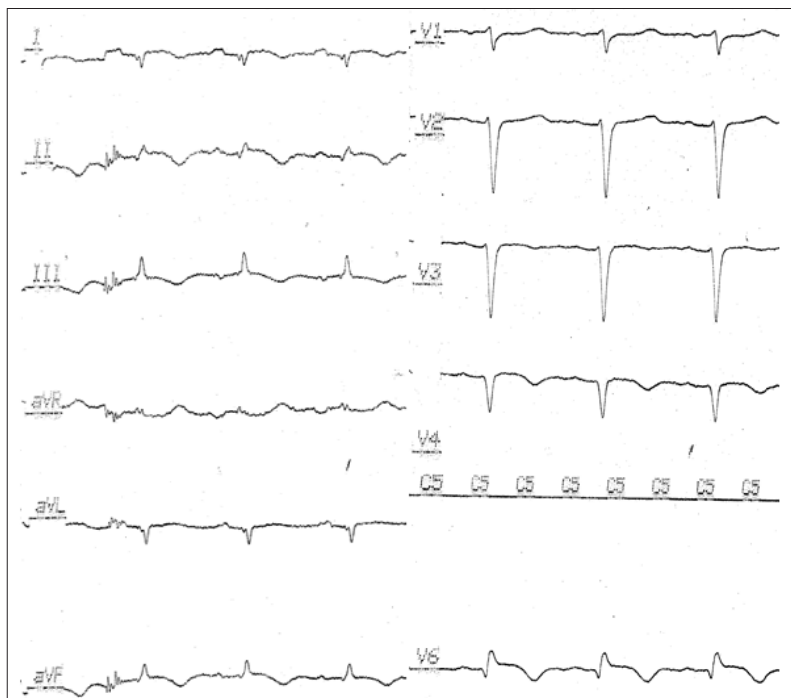**Phospholamban**

In the Dutch population this sort of gene mutation is endemic with a rate of about 15%. The ECG presents with low voltage in limb leads and T-wave inversions inferolateral with a high begin in lead V3 up to V6. Figure 1 revealed a typical example of these ECG changes due to a mutation in phospholamban.

In a ECG follow-up developing right bundle branch block is a gene-specific finding with dominant QRS fragmentation.



**Figure 1:** Typical ECG sign of arrhythmogenic left ventricular cardiomyopathy with inferolateral T-wave inversions or flattening with high begin and low voltage in limb leads due to phospholamban mutation



**Figure 2:** Typical lamin A/C ECG with left posterior fascicular block, low voltage in limb leads, anteroseptal R wave reduction, T-wave inversion inferolateral, ST-segment elevation inferolateral and atrioventricular conduction block

### Lamin A/C

According to the literature (Quarta et al., 2012) and an own case, there are specific ECG findings like atrioventricular block 1°, anteroseptal R-wave reduction, low voltage in limb leads, inferolateral T-wave inversions, in some cases left posterior fascicular block, and ST segment elevation inferolateral for lamin A/C-positive cases, characterised by high risk for ventricular fibrillation and high-grade atrioventricular block.

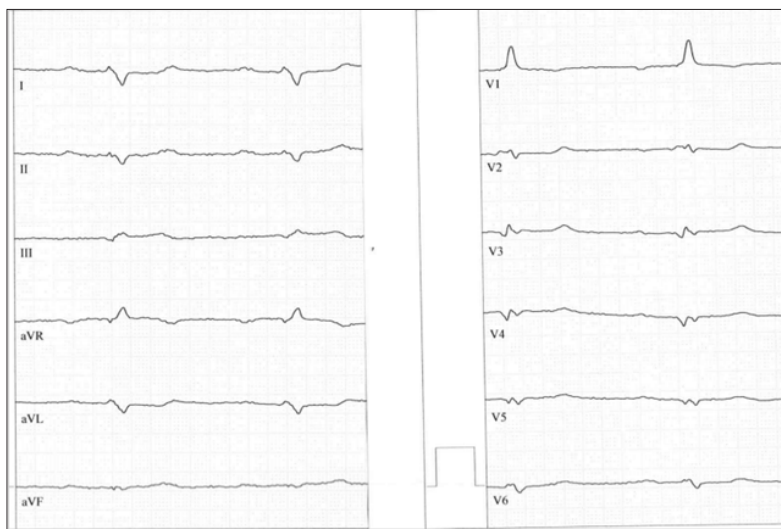
### Filamin C

In a few gene mutations in filamin C ECG is characterised by low voltage in limb leads in T-wave inversions inferolateral beginning at lead V4 up to V6.

### Desmoglein-2 and Desmocollin-2

Desmoglein-2 and desmocollin-2 are electrocardiographically characterised by right ventricular hypertrophy in about 50% of

cases beyond other typical ECG findings. Figure 3 revealed a typical example with low voltage in limb leads, a very rare left posterior fascicular block both characterizing decrease in left ventricular function, Q waves as electroanatomic scar, inferolateral QRS fragmentation, and dominant shaped R wave in lead V1 as a marker of right ventricular hypertrophy.



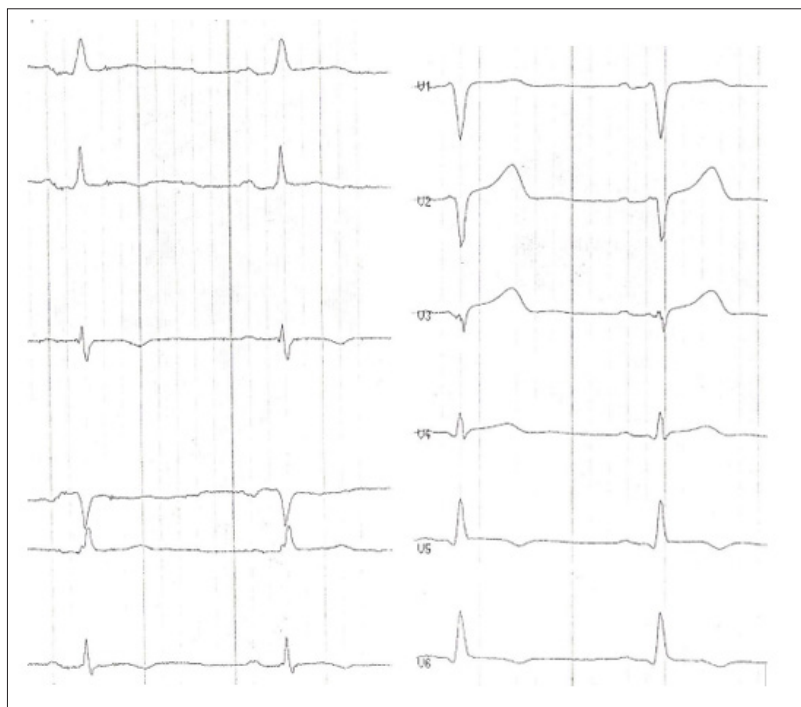
**Figure 3:** Typical example of desmoglein-2 or desmocollin-2 mutation of arrhythmogenic left ventricular cardiomyopathy with left posterior fascicular block, low voltage in limb leads, right and left significant Q-waves and dominant R wave in lead V1 characterising right ventricular hypertrophy

### Desmin

According to the literature, desmin-positive ECG's are characterized by low voltage in limb leads and T-wave inversions only in lateral leads V5 and V6.

### TMEM 43

The ECG in TMEM43-positive arrhythmogenic cardiomyopathy with left ventricular dominance is characterised by R-wave reduction in anteroseptal leads and no specific right ventricular T-wave inversion. T-wave inversions are inferolateral, mostly in lead V5 and V6. Figure 4 shows a typical example. TMEM mutations are first described in Newfoundland, USA and Canada, the founder gene probably originates in Germany.



**Figure 4:** Low voltage in limb leads and inferolateral T-wave inversions and anteroseptal reduction of R wave characterising TMEM43 mutations

## Discussion

Basically most ECG's reveal low voltage in limb leads and T-wave inversions or flattening in inferolateral leads. This is specially true in desmoplakin (Rampazzo et al., 2002), filamin C (Hespe et al., 2023) phospholamban mutations (Vafiadaki et al., 2023), and TMEM43 (Matos et al., 2023) mutations causing arrhythmogenic left dominant cardiomyopathy with right bundle branch block – like ventricular tachycardia (Belhassen et al., 2022). In these mutations the cut-off in lateral T-wave inversions vary a lot. In Desmoplakin and in TMEM43 lateral T-wave inversion is strictly in lead V5 and V6, in filamin C in lead V4 up to V6 and in phospholamban in lead V3 up to V6 according to a late enhancement inferoseptal in MRI (Peters, 2021). In most cases T-wave inversion in lead V2 is biphasic. In an ECG follow-up patients with phospholamban mutations develop a complete right bundle branch block with dominant QRS fragmentation and multiple epsilon waves (Peters, 2018). The second typical ECG due to lamin A/C mutation combines inferolateral T-wave inversion and low voltage in limb leads with anteroseptal R-wave reduction, ST-segment elevation inferolateral (Ni et al., 2024), and left posterior fascicular block. The key to lamin A/C is atrioventricular conduction delay.

The third typical ECG of arrhythmogenic left ventricular cardiomyopathy is a very rare form and is associated with desmoglein-2 (Pilichou et al., 2009) and desmocollin-2 mutations (Brodehl et al., 2017). A positive R/S ratio in lead V1 characterize right ventricular hypertrophy due to right ventricular myocyte cell necrosis (Peters, 2023). Left posterior fascicular block in combination with low voltage in limb leads characterizes poor left ventricular function. In comparison to desmoglein-2 positive right dominant arrhythmogenic cardiomyopathy typical right precordial epsilon waves and T-wave inversions are missing (Hermida et al., 2019; Peters & Wittinger, 2020). Another typical form of ECG in arrhythmogenic left ventricular cardiomyopathy is described by Calo (Calo et al., 2023; Calo et al., 2023) and is characterized by dominant R waves in lead V1. The described features are not only due to mutations of desmoglein-2 and desmocollin-2, but also in rare cases mutations in plakoglobin (Naxos disease) with a petrified right ventricle caused by myocyte cell necrosis (Basso et al., 2001) and right ventricular hypertrophy by ECG.

The fourth characteristic ECG findings caused by TMEM43 mutations are characterised by inferolateral T-wave inversion strictly in lead V5 and V6. However, the most important ECG finding in TMEM43 are basically anteroseptal R-wave reduction and missing right precordial T-wave inversions.

In conclusion, these four and probably more electrocardiographic features characterize arrhythmogenic left ventricular cardiomyopathy besides cardiac imaging especially cardiac MRI. The value of 12-lead ECG in arrhythmogenic left ventricular cardiomyopathy is outstanding importance. With a correct ECG analysis mutations of arrhythmogenic left ventricular cardiomyopathy can be defined for most mutations. Nevertheless, according to the latest cardiomyopathy guidelines

published in 2023 in the European Heart Journal the terms arrhythmogenic left ventricular cardiomyopathy and also non-compaction cardiomyopathy are missing and replaced by the term of non-dilated left ventricular cardiomyopathy (Arbelo et al., 2023).

## References

1. Kaplan, S. R., Gard, J. J., Carvajal-Huerta, L., Ruiz-Cabezas, J. C., Thiene, G., & Saffitz, J. E. (2004). Structural and molecular pathology of the heart in Carvajal syndrome. *Cardiovasc Pathol*, 13(1), 26-32. DOI: 10.1016/S1054-8807(03)00107-8
2. Corrado, D., Marra, P. M., Zorzi, A., Boffagna, G., Ciprinani, A., Lazzari, M., Migliore, F., Pilichou, K., Rampazzo, A., Rigato, I., Rizzo, S., Thiene, G., Anastasakis, A., Asimaki, A., Bucciarelli-Ducci, C., Haugaa, K. H., Marchlinski, F. E., Mazzanti, A., McKenna, W. J., Basso, C. (2020). Diagnosis of arrhythmogenic cardiomyopathy: The Padua criteria. *Int J Cardiol*, 319, 106-114. DOI: 10.1016/j.ijcard.2020.06.005
3. Quarta, G., Syrris, P., Ashworth, M., Jenkins, S., Zuborne Alapi, K., Morgan, J., Muir, A., Pantazis, A., McKenna, W. J., & Elliott, P. M. (2012). Mutations in the Lamin A/C gene mimic arrhythmogenic right ventricular cardiomyopathy. *Eur Heart J*, 33(9), 1128-36. DOI: 10.1093/eurheartj/ehr451
4. Rampazzo, A., Nava, A., Malacrid, S., Boffagna, G., Bauce, B., Rossi, V., Zimbello, R., Simionati, B., Basso, C., Thiene, G., Towbin, J. A., & Danieli, G. A. (2002). Mutation in human desmoplakin domain binding to plakoglobin causes dominant form of arrhythmogenic right ventricular cardiomyopathy. *Am J Hum Genet*, 71(5), 1200-1206. DOI: 10.1086/344208
5. Hespe, S., Isbister, J. C., Duflo, J., Puranik, R., Bagnall, R. D., Semsarian, C., Gray, B., & Ingles, J. (2023). A case series of patients with filamin C truncating variants attending a specialized cardiac genetic clinic. *Eur Heart J Case Rep*, 7(12), yta572. DOI: 10.1093/ehjcr/yta572
6. Vafiadaki, E., Glijnis, P., Doevendans, P. A., Kranias, E. G., & Sanoudou, D. (2023). Phospholamban R14del disease: The past, the present and the future. *Front. Cardiovasc. Med*, 10, 1162205. DOI: 10.3389/fcvm.2023.1162205
7. Matos, J., Helle, E., Care, M., Moayed, Y., Gollob, M. H., Thavendiarathan, P., Spears, D., & Hanneman, K. (2023). Cardiac MRI and clinical outcomes in TMEM43 arrhythmogenic cardiomyopathy. *Radiol Cardiovasc Imaging*, 5(6), e230155. DOI: 10.1148/ryct.230155
8. Belhassen, B., Laredo, M., Roudijk, R. W., Peretto, G., Zahavi, G., Sen-Chowdhry, S., Badenco, N., Te Riele, A. S. J. M., Sala, S., Duthoit, G., van Tintelen, J. P., Paglino, G., Sellal, J. M., Gasperetti, A., Arbelo, E., Andorin, A., Ninni, S., Rollin, A., Peichl, P., Milman, A. (2022). The prevalence of left and right bundle branch block morphology ventricular tachycardia amongst patients with arrhythmogenic cardiomyopathy and sustained ventricular tachycardia: insights from the European Survey of arrhythmogenic cardiomyopathy. *Europace*, 24(2), 285-295. DOI: 10.1093/europace/ueab190

9. Peters, S. (2021). History of phospholamban mutation in arrhythmogenic cardiomyopathy: a case report. *Mod. Appl. Med. Res*, 1(5), 04-05. Retrieved from [https://www.academia.edu/113767038/I\\_HISTORY\\_OF\\_PHOSPHOLAMBAN\\_MUTATION\\_IN\\_ARRHYTHMOGENIC\\_CARDIOMYOPATHY\\_A\\_CASE\\_REPORT?uc-sb-sw=66353458](https://www.academia.edu/113767038/I_HISTORY_OF_PHOSPHOLAMBAN_MUTATION_IN_ARRHYTHMOGENIC_CARDIOMYOPATHY_A_CASE_REPORT?uc-sb-sw=66353458)
10. Peters, S. (2018). Electrocardiographic criteria in founder mutations related to arrhythmogenic cardiomyopathy. *J Cardiol Cardiovasc Med*, 3, 006-007. DOI: 10.29328/journal.jccm.1001021
11. Ni, H., Wang, Q., Xu, W., Xu, M., & Cai, W. (2024). The rare cause of ST segment elevation in left precordial leads – diagnostic clues from subtle waveforms. *J Electrocardiol*, 84, 151-154. DOI: 10.1016/j.jelectrocard.2024.04.005
12. Pilichou, K., Remme, C. A., Basso, C., Campian, M. E., Rizzo, S., Barnett, P., Scicluna, B. P., Bauce, B., van den Hoff, M. J., de Bakker, J. M., Tan, H. L., Valente, M., Nava, A., Wilde, A. A., Moorman, A. F., Thiene, G., & Bezzina, C. R. (2009). Myocyte necrosis underlies progressive myocardial dystrophy in mouse *dsg2*-related arrhythmogenic right ventricular cardiomyopathy. *J Exp Med*, 206(8), 1787 – 802. DOI: 10.1084/jem.20090641
13. Brodehl, A., Belke, D. D., Garnett, L., Martens, K., Abdelfatah, N., Rodriguez, M., Diao, C., Chen, Y. X., Gordon, P. M., Nygren, A., & Gerull, B. (2017). Transgenic mice overexpressing desmocollin-2 (DSC2) develop cardiomyopathy associated with myocardial inflammation and fibrotic remodeling. *PLoS One*, 12(3), e0174019. DOI: 10.1371/journal.pone.0174019
14. Peters, S. (2023). Electrocardiographic signs of necrosis and calcification in arrhythmogenic cardiomyopathy. *Ann Cardiol Vasc Med*, 6(2), 1074. Retrieved from <https://meddocsonline.org/annals-of-cardiology-and-vascular-medicine/electrocardiographic-signs-of-necrosis-and-calcification-in-arrhythmogenic-cardiomyopathy.pdf>
15. Hermida, A., Fressart, V., Hidden-Lucet, F., Donal, E., Probst, V., Deharo, J. C., Chevalier, P., Klug, D., Mansencal, N., Delacretaz, E., Cosnay, P., Scanu, P., Extramiana, F., Keller, D. I., Rouanet, S., Charron, P., & Gandjbakhch, E. (2019). High risk of heart failure associated with desmoglein-2 mutations compared to plakophilin-2 mutations in arrhythmogenic right ventricular cardiomyopathy/dysplasia. *Eur J Heart Fail*, 21(6), 792 – 800. DOI: <https://doi.org/10.1002/ejhf.1423>
16. Peters, S. & Wittinger, T. (2020). Electrocardiographic signs of right ventricular hypertrophy in desmoglein-2 and plakophilin-2 related arrhythmogenic cardiomyopathy. *SL Clin Exp Cardiol*, 3(1), 120. Retrieved from <https://www.scientificliterature.org/Cardiology/Cardiology-20-120.pdf>
17. Calo, L., Oliviero, G., Crescenzi, C., Romeo, F., Matino, A., Bressi, E., Stefanini, M., Silveti, E., Danza, L., Rebecchi, M., Canestrelli, S., Fedele, E., Lanzillo, C., Fusco, A., De Ruvo, E. (2023). Electrocardiogram in arrhythmogenic cardiomyopathy. *Eur Heart J*, 25(Suppl C), C169-C172. DOI: 10.1093/eurheartjsupp/suad019
18. Calo, L., Crescenzi, C., Matino, A., Casella, M., Romeo, F., Cappellato, C., Bressi, E., Panattoni, G., Stolfo, D., Targetti, M., Toso, E., Musumeci, M. B., Tini, G., Ciabatti, M., Stefanini, M., Silveti, E., Stazi, A., Danza, M. L., Rebecchi, M. (2023). The diagnostic value of the 12-lead ECG in arrhythmogenic left ventricular cardiomyopathy: Novel ECG signs. *JACC Electrophysiol*, 9(12), 2615-2627. DOI: <https://doi.org/10.1016/j.jacep.2023.08.020>
19. Basso, C., Tsatsopoulou, A., Thiende, G., Anastasakis, A., Valente, M., & Protonotarios, N. (2001). “Petrified” Right Ventricle in Long-Standing Naxos Arrhythmogenic Right Ventricular Cardiomyopathy. *Circulation*, 104(23), E132-133. DOI: <https://doi.org/10.1161/hc4701.098570>
20. Arbelo, E., Protonotarios, A., Gimeno, J. R., Arbustini, E., Barriales-Villa, R., Basso, C., Bezzina, C. R., Biagini, E., Blom, N. A., de Boer, R. A., De Winter, T., Elliott, P. M., Flather, M., Garcia-Pavia, P., Haugaa, K. H., Ingles, J., Jurcut, R. O., Klaassen, S., Limongelli, G.... Kaski, J. P. (2023). 2023 ESC Guidelines for the management of cardiomyopathies: developed by the task force on the management of cardiomyopathies of the European Society of Cardiology (ESC). *Eur Heart J*, 44(37), 3503-3626. DOI: 10.1093/eurheartj/ehad194

**Copyright:** ©2024 Stefan Peters. This is an open-access article distributed under the terms of the Creative Commons Attribution License, which permits unrestricted use, distribution, and reproduction in any medium, provided the original author and source are credited.